

Every veterinarian knows this about our valued clientele...

When someone's dog needs specialized medical care...

there is one referral question that matters.

"If it was your dog, where would you go?"



This is the story of veterinarian Stacie Anderson and her dog Eliza.

**PATIENT** Eliza 3 yr-old, Springer Spaniel

**DIAGNOSIS** Canine Hip Dysplasia

**ELIZA'S OWNER** Stacie Anderson, DVM Coronado Animal Hospital, Sierra Vista, AZ

**PROCEDURE** Left Biomedtrix BFX® Total Hip Replacement



TREATING SURGEONS  
**Ross Lirtzman**  
DVM, DACVS



**Brian Trumpatori**  
DVM, DACVS-SA

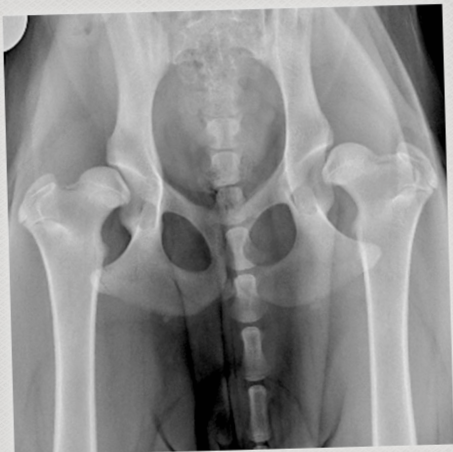**Dr. Stacie Anderson** came to us looking for fresh answers, optimism and hoping for a positive outcome, after two previous unsuccessful operations.

"I was at a loss and started asking around.

I was determined to find a solution for Eliza."

- Stacie Anderson, DVM

Arizona Canine Orthopedics is one of a select group of Total Hip Centers of Excellence in the western U.S. and has been recognized for quality for care, innovation, education and industry leadership.

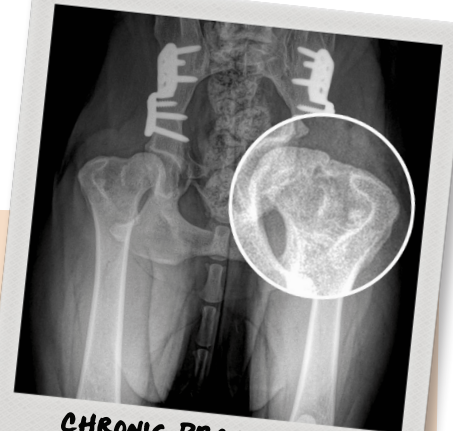

**HIP DYSPLASIA**

➤ Hip extended view of Eliza's hips as a juvenile are diagnostic of bilateral canine hip dysplasia characterized by hip subluxation, femoral head malformation and joint incongruency.

➤ At less than one year of age, Eliza was treated elsewhere by staged, bilateral, Double Pelvic Osteotomy (DPO) to try to salvage the dysplastic hip joints. DPO rotates the acetabular bone segment outwards to improve dorsal coverage of the femoral heads and, ideally, to create joint stability.

Despite DPO, rapidly progressive left hip osteoarthritis is seen with femoral neck thickening, femoral head malformation and peri-articular osteophytosis.



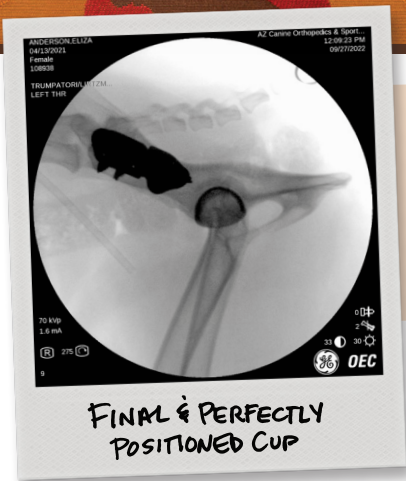**CHRONIC PROGRESSIVE BILATERAL HIP OSTEOARTHRITIS**



Arizona Canine Orthopedics & Sports Medicine

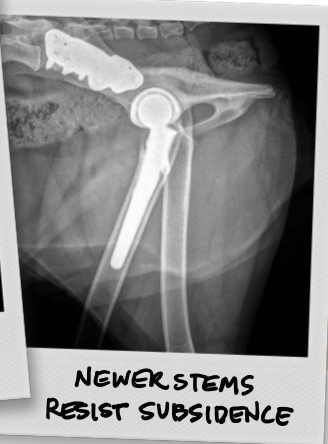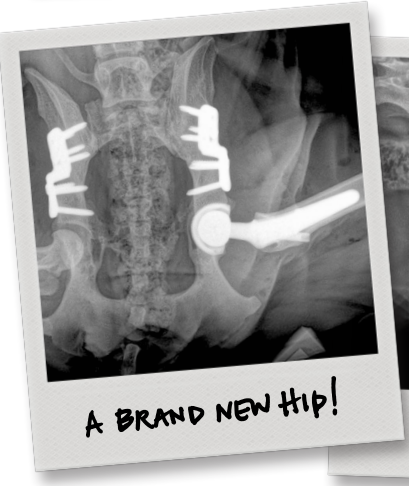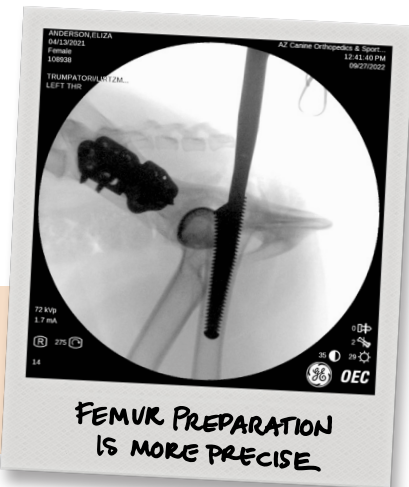7410 E. Pinnacle Peak Road • Scottsdale, Arizona 85255 • 480.998.5999 • arizonacanineorthopedics.com






◀ Intra-operative imaging of **the prosthetic acetabular cup** in the sagittal plane improves our ability to most accurately position this implant. In Eliza's case, the native acetabulum has been re-oriented by the DPO procedure and imaging is essential to appropriately implant the acetabular cup with respect to angle of lateral opening (ALO) and inclination.

▶ Intra-operative imaging of **femoral canal broaching** preparation in the frontal plane improves implant size selection and alignment of the femoral stem from medial to lateral.



◀ **Postoperative frog VD and lateral pelvis projections** of Eliza's left, Biomedtrix BFX® total hip replacement. Numerous features of the reduced hip can be seen in the sagittal plane - optimized femoral stem alignment, appropriate femoral anteversion, acetabular cup angle of lateral opening and inclination.

Both the acetabular cup and the augmented femoral stem are porous coated titanium and will allow for Eliza's own bone to grow into—and onto—the surfaces of the implants for long term biological fixation.



**"I believe Dr. Lirtzman and Dr. Trumpatori are among the best orthopedic surgeons in their profession. They**

replaced my dog's left hip with a perfect new artificial hip, and she had a smooth recovery thanks to their attention and care.

I trusted them to give her the best that there can possibly be, and they did not disappoint. The staff... were also amazing throughout her entire stay.

I'm over-the-top impressed by this place and genuinely believe it to be one of the best in the whole country, if not worldwide.

Eliza has never been so active and pain free! ♥♥♥♥  
150/10 LOVE this place!" - **Stacie Anderson**

**EVERYONE LOVES COUCH TIME AFTER A LONG DAY!**



**NOW SHE LITERALLY CLIMBS THE WALLS!**



**OUR GOAL:** To help practices understand that THR can be a consistent and reproducible procedure with low complication rates. Let's turn confusion into confidence so you can feel good about the decisions you make for your patients.

Scan Here for More Info



**Arizona Canine Orthopedics & Sports Medicine**

7410 E. Pinnacle Peak Road • Scottsdale, Arizona 85255 • 480.998.5999 • arizonacanineorthopedics.com